Case Report

Eosinophilic fasciitis in an infant: A case report and literature review

Taha I. Yousif[1], Abdullatif H. Alenazi[2], Abdulaziz A. Alkhateeb[3], Abdelmoneim Alaattaya[4]

[1]Consultant pediatrician, Johns Hopkins Aramco Healthcare, Southern area, Women and Children Department, KSA.
[2]Consultant Rheumatologist, Johns Hopkins Aramco Healthcare, Rheumatology department, KSA.
[3]Consultant dermatologist, Johns Hopkins Aramco Healthcare, Southern area, Dermatology department, KSA.
[4]Consultant Radiologist, Johns Hopkins Aramco Healthcare, Dhahran, KSA.

ABSTRACT

Introduction: Eosinophilic fasciitis (EF) is a rare connective tissue disorder characterised by skin hardening and hyperpigmentation. It is mainly triggered by viral and bacterial illnesses, vaccination, and trauma, mimicking morphoea. EF is well-reported in the adult population but rarely in pediatrics. Until 2024, around 300 pediatric cases have been reported worldwide since it was first described.
Case report: A 16-month-old infant with EF, who presented with tight, hard skin on the lower thighs and upper legs for a few weeks. The baby was on a Pavlik harness 23 hrs/day for developmental hip dysplasia, reduced gradually and removed completely one month before presentation. The lower limbs' skin was symmetrically tight, with peau d'orange features associated with dryness. Investigations, including skin biopsy, were nonconclusive. Auto-immune work-up was negative. An MRI of the legs and thighs identified changes consistent with EF. He was started on steroids and immunosuppressants and eventually biologics. He responded very well to tocilizumab, with improvement in skin hardening and hyperpigmentation. He has a normal range of movement.
Discussion: Although rare, pediatricians should be aware that EF can occur in children, more frequently than other autoimmune diseases, especially following the COVID-19 pandemic. To our knowledge, this is the youngest reported case of EF.
Keyword: Case report, Eosinophilic fasciitis, Linear scleroderma, Morphoea.

Introduction

Eosinophilic fasciitis (EF) is a rare connective tissue disorder characterised by skin hardening and hyperpigmentation. It is an immunological disorder primarily affecting adults. An immune stimulus, such as trauma, medications, or viral or bacterial infections, usually triggers EF.

Some reports classify EF at the extreme end of the morphoea spectrum because of its similar presentation. EF is rare in children and extremely rare in infants. Our aim is to enrich the literature on this rare disease and increase clinicians' awareness.

Access this article online	
Quick Response Code:	Website: www.smh-j.com
	DOI: 10.54293/smhj.v6i3.220

Address for correspondence: Taha I. Yousif, Consultant pediatrician, Johns Hopkins Aramco Healthcare, Southern area, Women and Children Department, KSA.
E-mail: Drtaha2002@yahoo.com
Received: 2 Aug 2026 **Accepted:** 19 Oct 2026
This is an open access article by SMHJ is licensed under Creative Commons Attribution 4.0 International License.
(https://creativecommons.org/licenses/by/4.0)

Please cite this article as: Yousif TI, Alkhateeb AA, Alenazi A, Alaattaya A. Eosinophilic fasciitis in an infant: a case report and literature review . SMHJ [Internet]. 2026;6(3):460-465.

© Saudi Medical Horizons Journal

CASE HISTORY

A 16-month-old boy presented to the outpatient clinic at Johns Hopkins Aramco Healthcare, Eastern Area, Saudi Arabia, early in 2026 with hyperpigmentation and hardening of the skin of the legs and the lower parts of both thighs. The condition began two months before presentation, initially with dry skin, for which topical hydrocortisone 1% was prescribed. It has progressed gradually to swelling, tightening and hyperpigmentation. There were no associated fever and no history of trauma. He has a history of bilateral developmental hip dysplasia, which required a Pavlik harness. This was applied 23 hours per day for the first two months and was gradually reduced thereafter. The harness was stopped a month before presentation. Clinical examination revealed bilateral lower-limb swelling of the legs and lower thighs, with associated skin hardening, hyperpigmentation, and Peau d'Orange changes (Figures 1- 4). Range of movement was preserved in the knees and ankles, with no joint stiffness. Face, hands and feet were not affected. The scalp was normal. There was no family history of skin disorders or any autoimmune diseases. The topical steroid treatment was changed to mometasone with mild improvement. The baby's initial investigations revealed a total white blood cell count of 15,000, with an Absolute Neutrophil Count (ANC) of 6,000, lymphocytes of 7.2%, and eosinophils of 0.9%. Haemoglobin was 11gm/dl, and platelets were 310,000/cum. Inflammatory markers were elevated, with CRP at 5.4 and ESR at 15. ASOT was 127.5, and ANA titre was 1:40. Liver and renal profiles were normal. The child was seen by the dermatology team, and extensive localised dermatitis and panniculitis were suspected. A skin biopsy was obtained; although not deep enough, it showed sclerotic changes in the dermis. The punch biopsy was not deep enough to exclude panniculitis. The biopsy of the right lower leg showed epidermis, dermis and superficial portions of subcutaneous fat. It is reported as "focal parakeratosis without significant epidermal acanthosis". There was mild perivascular, periadnexal, and interstitial inflammation, predominantly composed of lymphocytes. There appears to be mild fibrosis within the dermis that extends into the deep dermis and pannicular septa. PAS-D was negative for fungal microorganisms. CD3 demonstrated clusters of T-cells, while CD-20 staining was not specific. CD163 showed scattered interstitial histiocytes. The histopathologic features were nonspecific and appeared reactive, with features suggestive of early morphoea, stiff skin syndrome, or related entities. Clinically, a differential diagnosis included EF versus linear scleroderma. A rheumatology opinion was sought at this point. Autoimmune screening was performed. An MRI of the lower limbs, from the hips to the ankles, was performed with and without contrast (Figures 5, 6). This showed mild fascial thickening and mild enhancement in both lower limb muscles. Mainly in the superficial and, to a lesser extent, the deep fascia, with no collections or masses. Mild signal change was noted in the adjacent muscles, with preserved muscle bulk. The overlying skin was intact. The picture was suggestive of mild-to-moderate eosinophilic fasciitis. The child was started on oral steroids, which was followed later by methotrexate 7 mg in addition to folic acid once per week. He was seen at 21 months with a normal systemic examination and symmetrical hardening of the lower-limb skin, including the thighs, with some improvement; normal range of movement at the knees and ankles; and persistent hyperpigmentation and peau d'orange changes. As there was mild improvement, a decision was made to start tocilizumab injections, 162 mg every 2 weeks, in addition to methotrexate. He remained on biologics, now for 6 months, with significant improvement.

Discussion

Eosinophilic fasciitis, or Shulman's syndrome (described by Shulman in 1974), is a rare connective tissue disease. It primarily affects adults. Because it is rare in children, early diagnosis and treatment are challenging due to its acute onset and unknown aetiology [1]. Since it was first described in 1974, more than 300 pediatric cases have been reported [2]. EF usually presents with a symmetrical erythematous skin rash affecting the limbs and trunk, associated with hyperpigmentation and skin hardening, secondary to inflammation and thickening of the fascia, often accompanied by peripheral eosinophilia [3]. Because EF can be mistaken for morphoea, with similar presentation and triggers, some authors describe EF as the severe end of the morphoea spectrum [4]. EF may also present with arthralgia and reduced range of joint movement, leading to significant functional impairment and poor quality of life. Presentation may include Raynaud's phenomenon, systemic involvement with hepatosplenomegaly, joint contracture [4] and progression to skin fibrosis, which are more common in children than adults [5]. Although internal organ involvement is rare, some cases have reported restrictive lung disease, pleural effusion, and pericardial or renal involvement [1]. Presentation with polyarthralgia is common, affecting



Figure 1:Peau d' orange changes in the left thigh.



Figure 2:Right leg hyperpigmentation with dry skin.



Figure 3:Left leg skin hyperpigmentation.



Figure 4:Left thigh tightness .

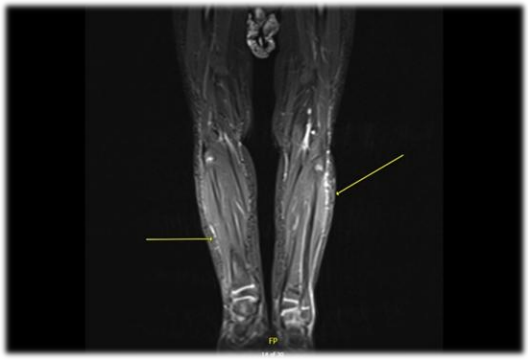

Figure 5: Coronal view of the legs showing fascial thickening (arrows).

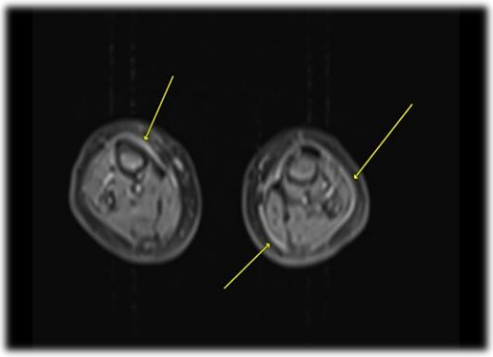

Figure 6:Transverse view showing fascial thickening (arrows).

8 of 11 paediatric patients in one study [6]. In addition, unusual presentation with progressive motility impairment with no skin involvement has also been reported, more in cases with late presentation [7]. Fortunately, our case showed only isolated skin involvement with no systemic, joint or motility concerns. The groove sign is pathognomonic. It results from fascial tethering to the overlying skin, with hyperpigmentation or hypopigmentation [1]. Another sign frequently seen in EF is the prayer sign [8]. We did not see these in our case. The aetiology of EF remains unclear; its pathogenesis is presumed to be autoimmune-driven [1]. A 2023 review reported different triggers across worldwide cases. These triggers include intensive exercise, trauma, viral and bacterial infections (e.g., Borrelia burgdorferi), surgery, other autoimmune diseases, insect bites, some medications, and even emotional tension [9]. In our case, we wonder whether the Pavlik harness is linked to the presentation. The infant was not on any medications, and there has been no history of recent infection. Blood tests were non-specific. The complete blood count was usually within normal limits, and peripheral eosinophilia was not required for diagnosis [10]. Hypergammaglobulinemia is commonly reported [2]. A study from 4 European countries involving 8 patients reported eosinophilia in 5 of 8 patients and hypergammaglobulinemia in 5 of 7 [3].

Magnetic resonance imaging helps guide diagnosis. It may show increased fascial signal intensity with contrast enhancement in the acute phase [10] as shown in our case. In a study by Cesar et al. [4] six of eight patients had MRI changes consistent with EF. Diagnosis is based on a deep skin biopsy involving the fascia. Characteristic features include oedema and inflammatory infiltrates of plasma cells, lymphocytes, eosinophils, and histiocytes within the deep fascia and subcutaneous tissue, resulting in fascial thickening that can progress to sclerosis with diminished inflammatory cellularity in later stages [1,2]. Due to the scarcity of cases in the pediatric population, diagnostic criteria are based on adult data [8]. Steroids are the first-line treatment, with most patients showing a good or partial response [3]. Some patients, however, relapse during or after steroid tapering, and others may show no response. The second-line treatment relies on immunosuppression. Agents used include methotrexate, azathioprine, mycophenolate or cyclosporine, usually combined with steroids, which showed good response, as well as rituximab [3]. New options could also play a role in treatment, including interleukin-6 inhibitors and biologics, which have been reported in multiple cases. Stubbs et al. [8] reported six cases of EF over 12 years at a single rheumatology centre, mostly in females. The youngest was four years of age. Our patient is an infant who was only 16 months at the time of diagnosis, the youngest to be reported in the literature, to our knowledge. Most of the patients responded well to steroids and MTX. Use of hydroxychloroquine, MMF, and biologics such as rituximab and tocilizumab were required depending on the severity. Erez et al. [3] reported three cases with resistant EF who responded very well to rituximab and IVIG. No association with malignancy or trauma was reported. They did not report any systemic involvement in their cohort, like our case.

Prognosis: In terms of prognosis, 21 cases of EF in the pediatric population were followed [8]. Two-thirds of the patients developed skin fibrosis at long-term follow-up, while one-third had complete resolution with no residual symptoms. Children younger than 7 years old were twice as likely to develop skin fibrosis, compared to their older peers. Our patient is a young infant who falls into this category. Although he is currently improving, close follow-up is required to monitor contractures and other complications.

Ethical considerations: Informed consent was obtained from the child's father to present the case. Consent included taking photos and publishing the case. Ethical approval was obtained from the Research and Development department of Johns Hopkins Aramco Healthcare. The study was conducted in accordance with the Declaration of Helsinki

Conclusion

We report an interesting case of EF. To our knowledge, this is the youngest case reported in the literature. The infant showed a mild response to steroids combined with methotrexate and is now on tocilizumab with significant improvement. We wonder whether the Palvik harness triggered this. We highlight this rare presentation to increase awareness and improve global knowledge in paediatrics.

Conflict of Interest

None

Funding

None

References

1. Cherim A, Bastian A E, Popp C, Mihon L, Efrem I, Vreju A, et al. Eosinophilic fasciitis: unravelling the clinical tapestry of a rare case and review of literature. Rom J Morphol Embryol. 2024; 65(2):341-347.

2. Knapp S, Bolko L, Servettaz A, Didier K. Eosinophilic fasciitis: From pathophysiology to therapeutics. Rev Med Interne. 2024; 45(8):488-497.
3. Erez D, Shoenfeld Y, Natour A, Dovrish Z, Tayer-Shifman OE, Levy Y. Clinical experience with biologic treatment in resistant eosinophilic fasciitis: Case reports and review of the literature. Medicine (Baltimore). 2021;100(13):e25359.
4. Merten JS, Seyge MMB, Thurlings RM, Radstake TRDJ. De Jong EMGJ Morphea and eosinophilic fasciitis: An update. American Journal of Clinical Dermatology. 2017; 18(4):491–512.
5. César T, Giovannini D, Deroux A, Bouillet L, Nugues F, Carbasse A, et al. Pediatric eosinophilic fasciitis: Similarities and differences with adult forms. Eur J Pediatr. 2025; 184(2):156.
6. N. Blaseg, E. Newman, K. James. Eosinophilic fasciitis in pediatric patients: A single center case series. Annals of Allergy, Asthma & Immunology. 2024; 133(6):S82.
7. Papa R., Nozza P., Granata C., Caorsi R., Gattorno M., Maertini A., et al. Juvenile eosinophilic fasciitis: Three case reports with review of the literature. Clinical and Experimental Rheumatology. 2016; 34(3), 527–530.
8. Stubbs LA, Ogunbona O, Beil E, Szafron V, Adesina A, Anvari S, et al. Juvenile eosinophilic fasciitis: A single center case series. Pediatr Rheumatol. 2024; 22(1):29.
9. Wosiak A, Biernacka-Zielińska M, Roszkiewicz J, Smolewska E., Diffuse fasciitis with eosinophilia in boys: A case-based review. Rheumatology International. 2023; 43:1755–1764.
10. Romanowska-Próchnicka K, Dziewit M, Lesiak A, Reich A, Olesińska M. Scleroderma and scleroderma-like syndromes. Front Immunol. 2024; 15:1351675.